



PUBLICATIONS OF THE MUSEUM  
TEXAS TECH UNIVERSITY

Two publications of The Museum of Texas Tech University are issued under the auspices of the Dean of The Graduate School and Director of Academic Publications, and in cooperation with the International Center for Arid and Semi-Arid Land Studies. Shorter research papers are published as Occasional Papers, whereas longer contributions appear as Special Publications. Both are numbered separately and published on an irregular basis.

Institutional libraries interested in exchanging publications may obtain the Occasional Papers and Special Publications by addressing the Exchange Librarian, Texas Tech University, Lubbock, Texas 79409. Individuals may purchase separate numbers of the Occasional Papers for 50 cents each through the Exchange Librarian. Remittance must be enclosed with request.

S-NA-Lubbock

MUS. COMP. ZOO.  
LIBRARY  
SEP 13 1976  
HARVARD  
UNIVERSITY

# OCCASIONAL PAPERS THE MUSEUM TEXAS TECH UNIVERSITY

NUMBER 42

10 SEPTEMBER 1976

## HISTOLOGICAL AND SCANNING ELECTRON MICROSCOPIC STUDIES OF TOOTH STRUCTURE AND THEGOSIS IN THE COMMON VAMPIRE BAT, *DESMODUS ROTUNDUS*

CARLETON J. PHILLIPS AND BARRY STEINBERG

Vampire bats, particularly the species *Desmodus rotundus*, have been studied in considerable detail in recent years. It is not surprising that the restricted sanguivorous feeding habit of these bats is reflected in their highly specialized morphological characteristics and physiological capabilities (for example, Forman, 1972; DiSanto, 1960; Horst, 1968). The dentitions of *Desmodus* and related *Diphylla ecaudata* have attracted considerable attention, primarily because of a marked reduction in number of permanent teeth (20) and obvious specializations in coronal morphology and occlusal pattern (Villa-R., 1966; Slaughter, 1970; Miller, 1896; Birney and Timm, 1975; Greenhall, 1972).

When teeth of *Desmodus* are examined grossly they always are impressively sharp; indeed, even in old individuals they are nearly razorlike. Maintenance of sharp cutting edges, especially on the upper and lower canines and large upper incisors, clearly is of importance to survival of individual vampire bats. Considering that individual *Desmodus rotundus* possibly live 10 or more years, the mechanisms of tooth-sharpening and replacement of dental tissues are of obvious interest if we are to understand the evolutionary biology of this species. The authors recently have had an opportunity to investigate these aspects of dentition of *Desmodus rotundus* as a part of general studies of chiropteran oral biology.

## MATERIALS AND METHODS

Specimens of adult *Desmodus rotundus* were collected by the senior author in Jalisco, México, in 1972 and 1973. They were preserved, in toto, in 10 per cent buffered or nonbuffered formalin and then stored in 70 per cent alcohol. Jaws were removed from two specimens, decalcified in Decal (Scientific Products), dehydrated, cleared in xylene, and embedded in paraplast with vacuum infiltration. Sections were cut at seven microns and stained with Harris' hematoxylin and eosin-Y (H&E), the periodic acid-Schiff's (PAS) reaction, or Masson trichrome. Formulae and interpretation of these histological preparations are based on Lillie (1965) and Sicher and Bhaskar (1972). Jaws were removed from two other specimens, mounted on aluminum stubs, and coated with gold-palladium by means of a Hitachi HUS-4 GB evaporator. These latter specimens then were studied with a Hitachi HHS-2R scanning electron microscope and photographed with Polaroid 55 P/N film.

Reference slides are deposited in the Department of Biology, Hofstra University, and voucher specimens of *Desmodus* from the study sample are housed in The Museum, Texas Tech University.

## RESULTS

When viewed with a dissecting microscope, the dentition of *Desmodus rotundus* at first appears to be structurally the same as that of other microchiropterans and, thus, typically mammalian. The teeth are hard and their surfaces relatively smooth and consistent. In specimens fixed with formalin and stored in alcohol, edges of the teeth are somewhat translucent due to the typically sclerotic nature of the dentin. Examination of histological preparations indicated to us that teeth of adult *Desmodus* lack the outer enamel layer characteristic of most mammalian teeth. Study of the sections revealed that the primary coronal dentin usually was covered with acellular cement (Fig. 1) of variable thickness. Views of coronal surfaces at 1000 to 2500  $\times$  with the scanning electron microscope substantiated these histological observations. The teeth of all four specimens of *Desmodus rotundus* lacked enamel. Indeed, in Fig. 2, one can see exposed dentinal tubules on the posterolingual surface of an upper canine. In this place the tooth lacked even a layer of cement.

Overall examination of coronal surfaces of canines and incisors revealed relatively deep, unidirectional striae characteristic of thegnosis (Figs. 2-4). The locations of these striae on coronal surfaces

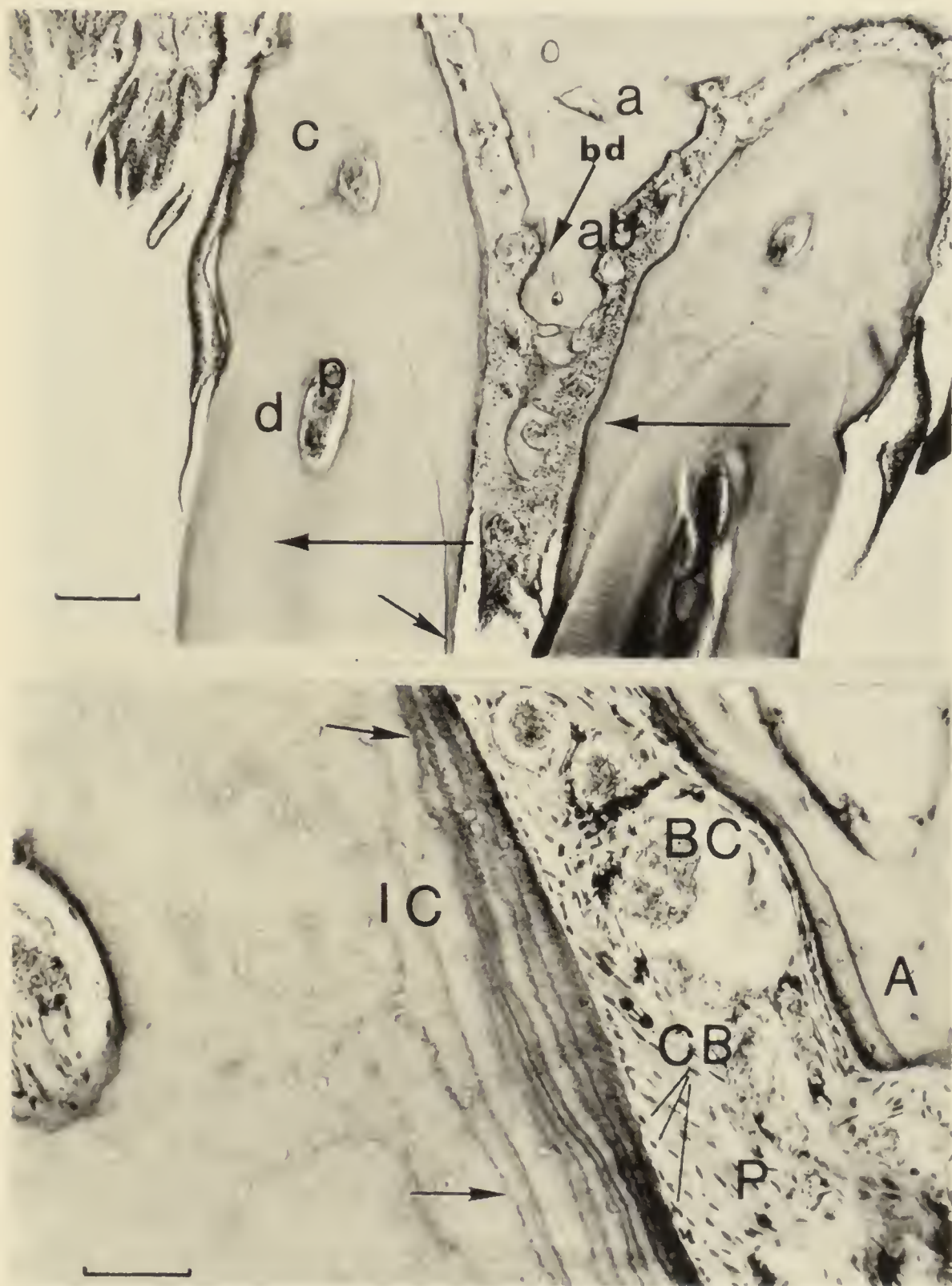


FIG. 1.—*Top*: Anterior view of upper inner incisors showing hypercementosis, incremental lines in cementum, coronal cementum (arrow), periodontium, direction of dental drift (horizontal arrows), and interdental septum. Abbreviations are: a, alveolar bone; ab, bone resorption; bd, bone deposition; c, cement; d, dentin; p, pulp. H&E; scale equals 200 microns. *Bottom*: Higher magnification of cement and adjacent tissue, showing typical variability in numbers of incremental lines (arrows). Abbreviations are: A, alveolar bone; BC, red blood cells in periodontal vessel; CB, nuclei of cementoblasts; P, periodontal ligaments; IC, incremental layers of cement. H&E; scale equals 50 microns.

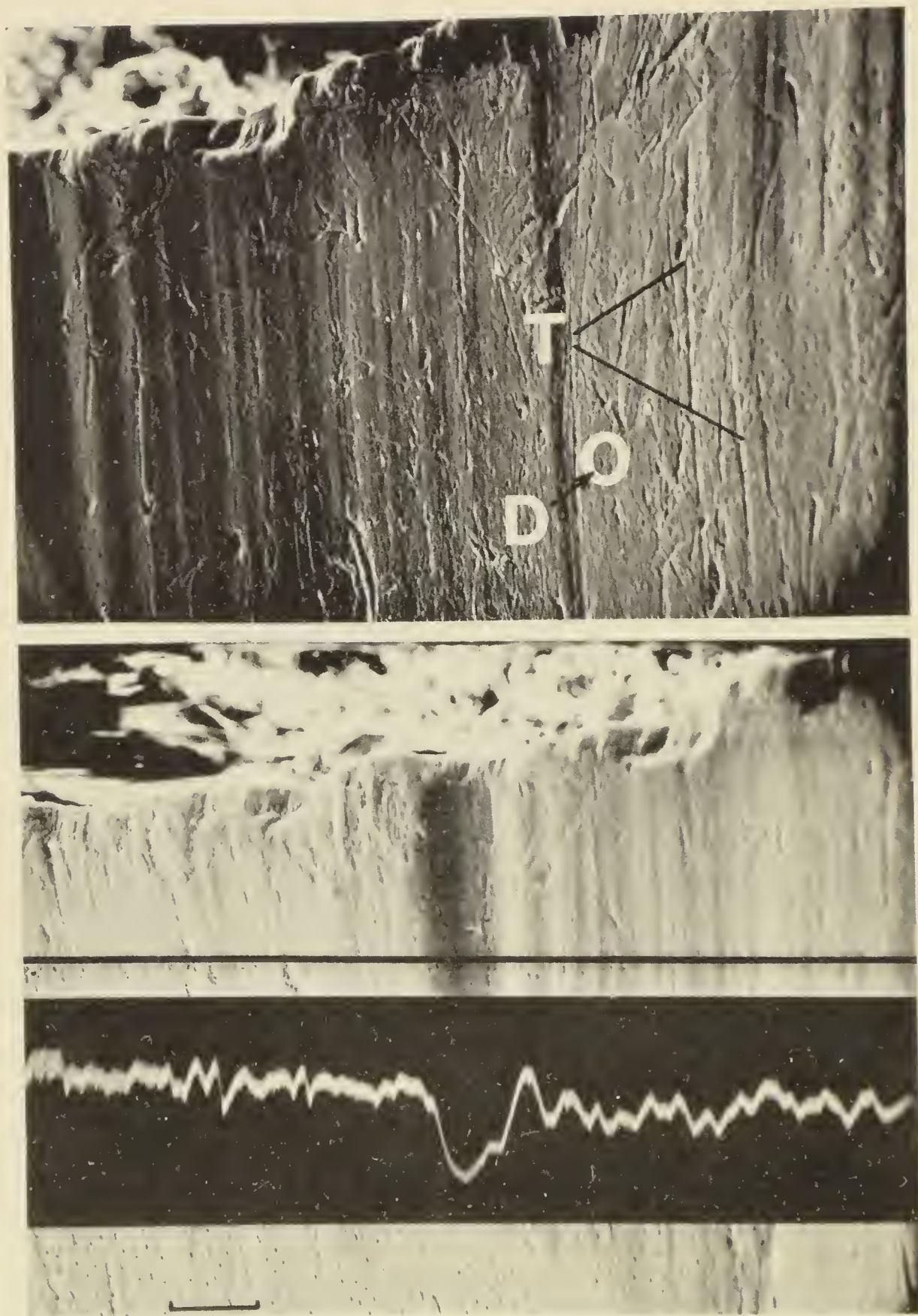


FIG. 2.—*Top*: Scanning electron microscope view of posterolingual surface of upper canine (see Fig. 4) showing exposed dentinal tubules (D) and deep thegosis striae (T). *Bottom*: Scanning electron microscope view of posterolingual surface of upper canine with superimposed scan analysis line showing topographical features of the tooth along the black line. Scale for both photographs equals 20 microns.

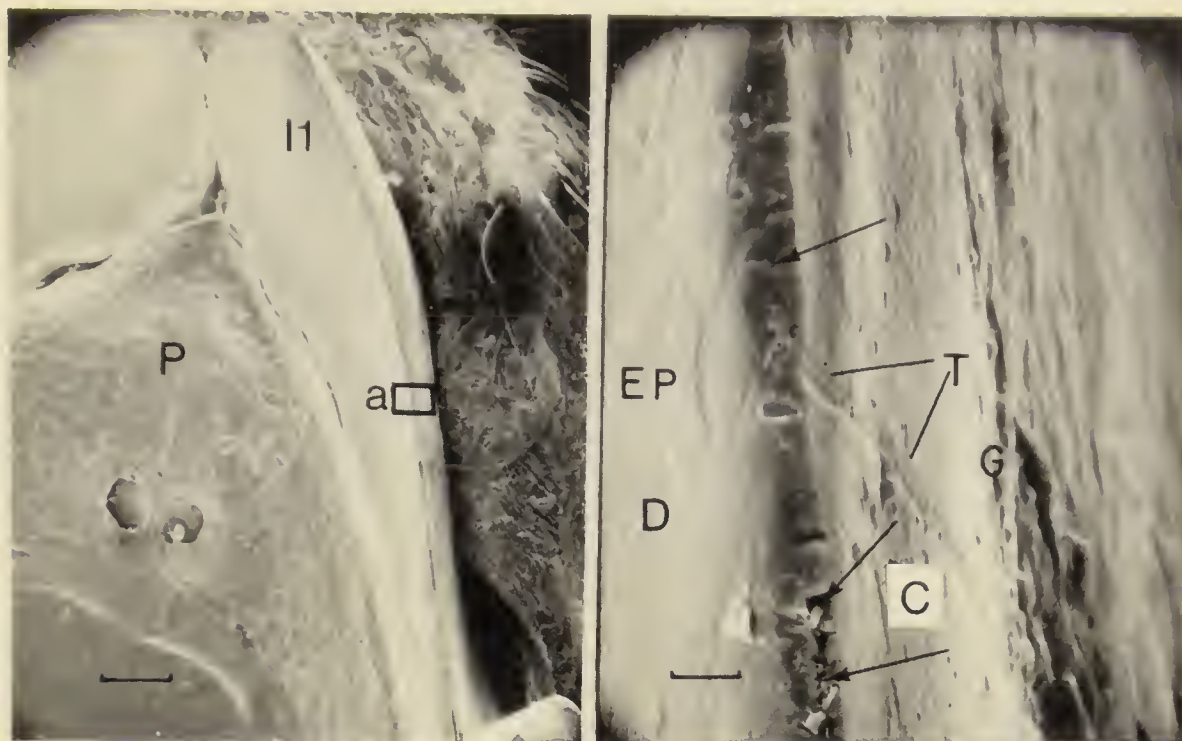


FIG. 3.—*Left*: Scanning electron microscope view (ventral) of first upper incisors showing palate (P) and area (a) enlarged in illustration at right. Scale equals 500 microns. *Right*: Scanning electron microscope view of upper incisor (area a in photograph at left) showing fracturing (arrows) and the edge maintained by thegosis. Abbreviations are: C, cement; D, dentin; EP, epithelial cell; G, globular dental plaque; T, thegosis striae. Scale equals 5 microns.

could be related to occlusal pattern in *Desmodus*. For example, the striae shown in Fig. 3 were located in the cementoid covering of the labial surface of an upper incisor. Unidirectional striae were lacking from the primary dentin surface of the lingual side. The cutting edge of the large upper incisors, especially at the anterior-most surface, is extremely sharp in *Desmodus*. Sharpening of the upper incisors was found to result frequently in slight fracturing of the cementoid layer at the cutting edge (Fig. 3).

Longitudinal thegosis striae, which were prominent on the dentin of the posterolingual surface of the upper canines, were caused by occlusal contact with the comparable coronal feature of the lower canines (Fig. 2). Edges of these striae were sharper and more distinct than typical thegosis striae on cementoid surfaces (compare Figs. 2 and 4). The effect of shearing tooth-to-tooth contact on dentinal surfaces was examined topographically by means of the scanning electron microscope line analysis mode (Fig. 2). The affected surface was extremely uneven and, in the example illustrated, included a deep, rounded groove that did not appear to have been caused by occlusion.

Some of the longest and most prominent thegosis striae were found on the flat anterior surfaces of the upper canines, which are struck

during occlusion by the posterior face of the lower canines (Fig. 4). Most (about 75 per cent) of the striae on the anterior face of the upper canines were oriented along the long axis of the crown; thegosis produces pointed apices on these teeth. The remaining striae, again clearly a pattern, were arranged obliquely across the face of this surface. Thegosis here contributed to a sharpened longitudinal edge.

Sharpening of teeth obviously is a form of attrition; the histological studies, which could reflect tissue responses to coronal stresses, thus were of special interest. Extensive hypercementosis was found in the sections examined (Fig. 1). The specimen figured was an adult and possibly was relatively old inasmuch as the bulk of the rooted portions of the teeth consisted of cellular cement. The dental pulp, which was largely necrotic in one of the specimens, was contiguous with the periodontal tissue even though the root apices were extended greatly by formation of new cement (Fig. 1). As would be expected, the coronal portion of the pulp in this individual was reduced in height by formation of irregular reparative dentin, in response to coronal attrition. Incremental lines were prominent in the cellular cement and alveolar bone. These lines represent irregular deposition of new cement and illustrate the continuing eruptive movements and drift of the teeth in *Desmodus*. The degree and direction of drift was not the same in any two teeth, even in the paired upper incisors shown in Fig. 1. Here, the incisor on the left apparently had drifted laterally whereas the one on the right displayed incremental lines on both sides (Fig. 1). Examination of adjacent alveolar bone revealed that in this individual the bone on the right side of the interdental septum was being resorbed, whereas on the left side some new bone had been deposited (Fig. 1). In this instance, the teeth possibly were moving in the same direction.

Comparison of incremental lines in cement of different teeth and from different portions of the same tooth within an individual revealed wide variation in number and thickness. Number of incremental lines varied in even relatively short regions along rooted portions of teeth (Fig. 1).

Two general aspects of oral biology of *Desmodus* also were noted in the course of examination of crowns with the scanning electron microscope. Isolated epithelial cells were found frequently, especially on lingual surfaces of the teeth (Fig. 3). Globular deposits, representing dental plaque formation, were found on coronal tooth surfaces that were relatively free of thegosis striae (Fig. 3). Groups of coccus-type microorganisms were seen in considerable numbers in conjunction with both dental plaque and epithelial cells when examined at ap-

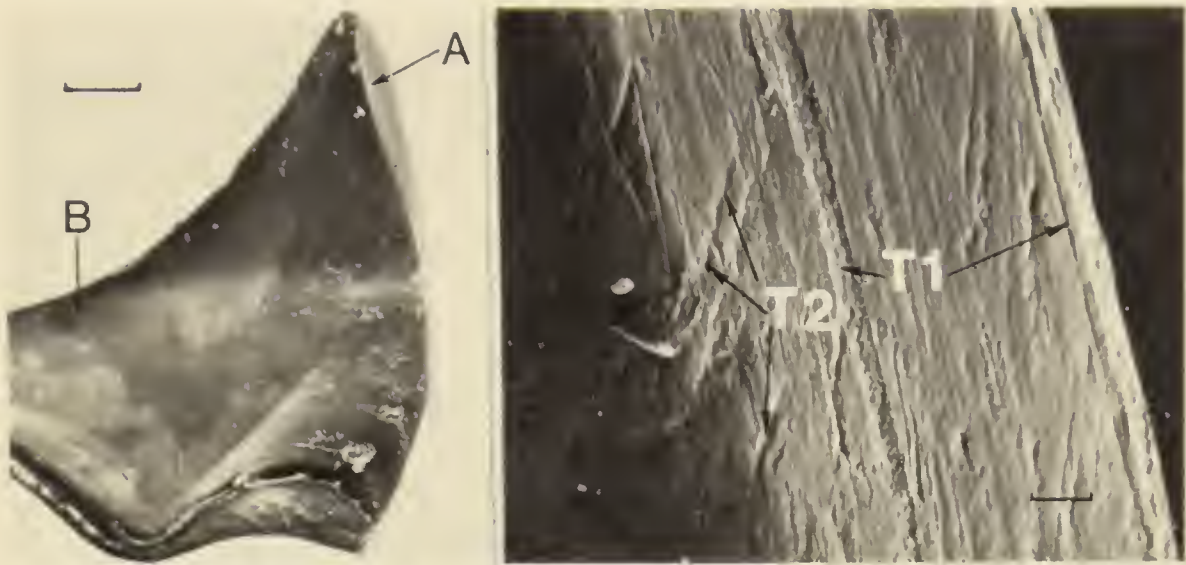


FIG. 4.—*Left*: Scanning electron microscope view of lingual surface of right upper canine. Area A is shown in higher magnification at right, and area B is illustrated in Fig. 2. Scale equals 500 microns. *Right*: Scanning electron microscope view of longitudinal (T 1) and oblique (T 2) thegosis striae on the anterior coronal surface of the canine shown at left. Such striae, due to irregularities in the sharpening surfaces, reflect mandibular movements. Scale equals 5 microns.

appropriate magnification ( $2000\times$ ). Overall, however, dental plaque was not extensive and clearly was restricted in distribution, possibly because of the high level of shearing tooth-to-tooth contact.

#### DISCUSSION

It is thought that the teeth of nearly all mammals are covered with a highly mineralized layer of enamel. However, the reduced dentition of *Desmodus rotundus* apparently is an exception. Examination of the relatively small teeth of this species with a dissecting microscope and a scanning electron microscope clearly reveals an unusual coronal structure. Hereditary enamel defects in man can have pathological consequences (Pindborg, 1970), but in the common vampire bat the apparent absence or, at least, reduction of this layer is of adaptive significance.

Attrition to crowns of typical mammalian teeth, which are comprised of dentin covered by enamel, can produce sharp edges. However, when a coronal apex is sheared away the enamel tends to be elevated in comparison to the softer, less mineralized dentin (Fig. 5). The resultant uneven surface pattern has been described for other mammals; for example, the molars of meadow voles (*Microtus*) undergo primary development, growth, and active eruption throughout life (Phillips and Oxberry, 1972, unpublished data). The teeth of vampire bats probably are much less resistant to thegosis attrition than they

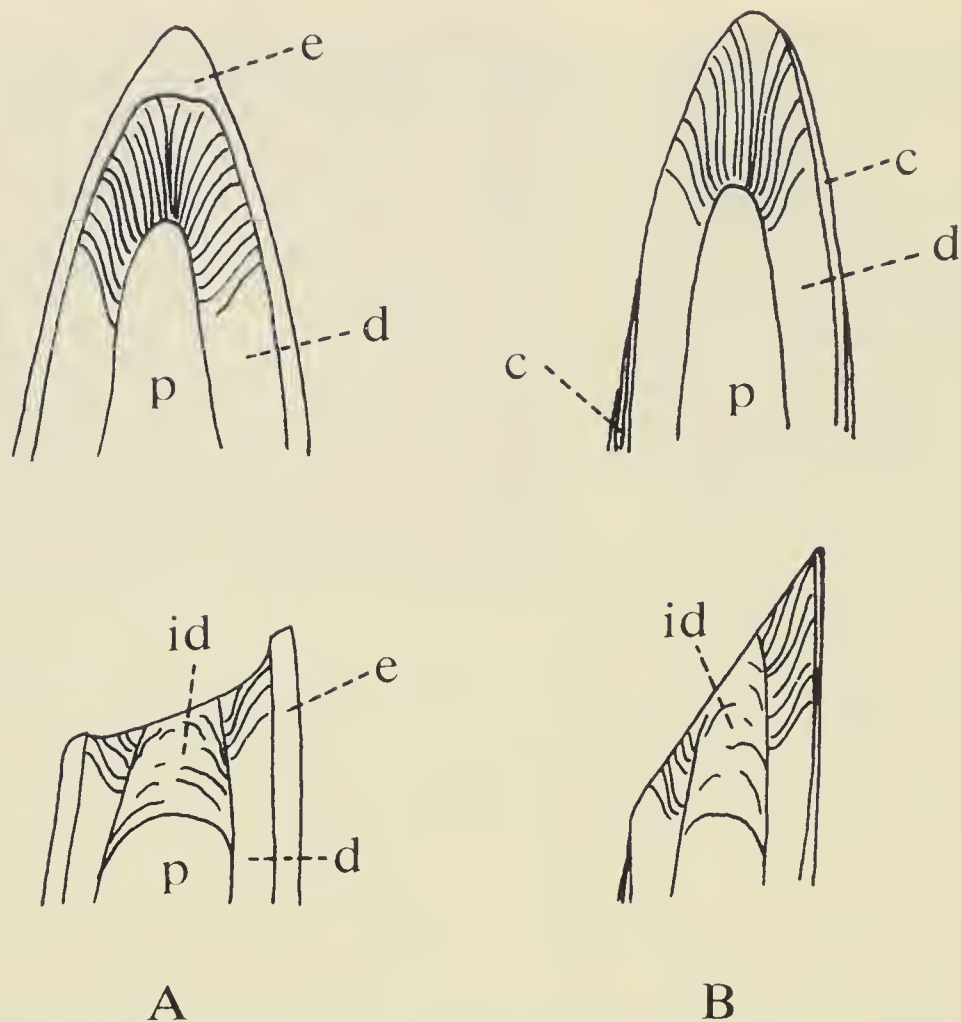


FIG. 5.—*A*: Diagrammatic view of typical abrasion and thegosis of a mammalian tooth covered by a layer of enamel. *B*: Diagrammatic view of abrasion and thegosis to a tooth lacking enamel. Abbreviations are: e, enamel; d, dentin; c, cement; id, irregular (reparative) dentin; p, pulp.

would be if covered by enamel. Additionally, because the hardness of dentin is more like that of cement than that of enamel, edges produced by thegosis are essentially even and sharp (Fig. 5).

Thegosis, or tooth sharpening, can be regarded as one component of bimodal attrition. Irregularities in sharpening surfaces result in microscopic scratches (striae) indicative of the process. Most previous analyses have dealt with paleontological materials (for example, Every and Kühne, 1971; MacIntyre, 1966), although thegosis has been found and described in *Leptonycteris*, a glossophagine bat (Phillips *et al.*, 1976). In vampire bats, the adaptive significance of maintaining extremely sharp teeth is obvious. Razorlike teeth allow these bats to initiate quickly a wound with minimal disturbance to the host. Observed behavioral patterns in captive and wild vampire bats underscore this point (Greenhall, 1972). *Desmodus* utilizes a careful, stalking gait and is said to approach "stealthily" a supply of blood, even under laboratory conditions (Greenhall, 1965).

As was first discussed by Greenhall (1972), the set of the dental arcade and notable degree of underbite in *Desmodus* allow for a pattern of tooth-to-tooth contact that produces sharpening of appropriate surfaces. Other authors (for example, Birney and Timm, 1975) previously have described the underbite and mandibular pits characteristic of vampire bats and have suggested an additional protective function. Mandibular motion has been studied in *Myotis*, among the Chiroptera (Kallen and Gans, 1972), in connection with mastication. The directionality of the gosis striae on the canines of *Desmodus* (Fig. 4) suggest at least two courses of mandibular movement. First, longitudinal striae apparently result from an essentially vertical component, and, second, oblique striae apparently are due to an angular component. Vertical mandibular motion and consequent tooth-to-tooth contact tend to sharpen coronal apices whereas angular movements maintain sharpened longitudinal surfaces, particularly on the canines. There are at least two components (vertical and angular) to mandibular movement in *Desmodus*, even though mastication is not a factor in feeding. Comparison of the temporal joint with that of other species having different mandibular masticatory motions would be valuable.

The origin and evolution of the Desmodontinae are unknown. A variety of investigations have shown clearly that these species are anatomically, behaviorally, and physiologically highly specialized (for example, Forman, 1972; DiSanto, 1960; Horst, 1968; Greenhall, 1965). Nevertheless, fundamental phenotypic features such as chromosomal morphology, serum proteins, and sperm morphology indicate close genetic affinity with the Phyllostomatidae (Forman *et al.*, 1968). In a review of chiropteran dentitions, Slaughter (1970) hypothesized that vampire bats evolved from frugivorous forms that required robust, sharp teeth for cutting through rinds of fruit. Such might well have been the case, although solid evidence is lacking. In evolutionary terms, the present study allows us to list and discuss several general characteristics of mammalian tooth development that clearly were of preadaptive value in the evolution of dentition of *Desmodus*: 1) Mammalian teeth are not dependent on enamel or, more strictly, ectoderm for determination of tooth shape (Sicher and Bhaskar, 1972; Osborn, 1973). Even in the absence of ectoderm, a mesodermal tooth germ will still result in an essentially normal tooth, insofar as the crown is concerned. 2) Cementoblasts will differentiate and produce a cementoid layer if enamel or dentin come into contact with periodontal tissue in the course of dental morphogenesis (Sicher and Bhaskar, 1972; Phillips and Oxberry, 1972). The coronal cementoid layer in *Desmodus* seemingly results from a lack of protective

enamel epithelium. Histological studies have not been done on advanced embryos but most certainly would reveal an absence of ectodermal cells separating newly formed primary dentin from surrounding periodontal tissues, at least along the basal two-thirds of the crown. At the same time, however, the established role of enamel epithelium in tooth eruption (Fullmer, 1967; Sicher and Bhaskar, 1972; Phillips, 1971), raises the question of how teeth of vampire bats erupt without the impactation common with enamel abnormalities in man (Pindborg, 1970). 3) Active attrition of coronal surfaces eventually would lead to a loss of teeth were it not for continuing eruption and replacement of tissue. Based on laboratory studies, even those teeth having closed roots continue to shift position, subsequent to the growth phase (the time during which teeth move into the occlusal eruptive plane), in response to a variety of factors (Sicher and Bhaskar, 1972; Glickman, 1972). The addition of cement onto roots of teeth has the effect of maintaining the length of the rooted portion. Deposition of cement on roots of vampire teeth is so extensive that it can be termed hypercementosis. In man, hypercementosis can have variable etiology; for example, it can be a general response to occlusal, or even hereditary, forces (Glickman, 1972). In *Desmodus*, continuous tooth eruption and deposition of cement were important preadaptive factors to the evolution of a dental system contingent on thegosis and consequent attrition.

A relatively large number of studies have been done previously on use of cementoid layers for age determination in mammals. Klevezal and Kleinenberg (1969) have stated that annual deposition of cementum occurs in several species of insectivorous bats. The present study of *Desmodus* provided no data to support the application of such a technique to this species. The number of cementoid incremental lines can be highly variable within a given tooth (Fig. 1). Indeed, when one studies a large number of sections cut in different planes, the variability is striking. Additionally, in view of the considerable occlusal stresses on the teeth in *Desmodus*, and in the absence of a known annual event that could affect deposition of cementum in both sexes, it would be surprising to find annual incremental lines.

The presence of isolated epithelial cells, dental plaque, and bacteria on tooth surfaces in *Desmodus* were not surprising. An interrelationship between salivary glycoproteins (mobile mucous phase), bacteria, and diet on the one hand and dental plaque on the other has been suggested but is not fully understood (Klinkhamer, 1968), at least insofar as man is concerned. The presence of plaque on teeth

of vampire bats, in which the diet is restricted to blood, thus is of interest. Judging from the abundance of saliva-resistant PAS-positive secretory materials in the salivary gland secretory acini and in certain of the striated ducts (DiSanto, 1960), it can be suggested that the saliva in *Desmodus* is mucosubstance rich (following terminology of Shackelford and Wilborn, 1968) and possibly is involved directly in plaque formation. Future studies might elucidate the local bacteriological conditions involved in dental plaque formation on teeth in these bats.

#### ACKNOWLEDGMENTS

Most financial support for the investigation reported here was from an NIH (National Institutes of Dental Research) research grant, DE 03455-02, to Phillips. Additional support was from a National Science Foundation Institutional research grant to Hofstra University (funds awarded to Phillips in 1972 and 1973) and from the Department of Biology, Hofstra University. We are especially grateful to Dr. Irving Galinsky for the latter support. We are pleased also to acknowledge the assistance of Drs. Bernardo Villa-R. and Ticul Alvarez-S., Departamento de Conservación, Secretaría de Agricultura y Ganadería, México, and John R. Richardson, NIH, Atlanta, in arranging for necessary collecting and importation permits. Valuable field assistance was given by Dr. Edward Snoek and Messrs. Brett Oxberry and Paul Billeter, Department of Biology, Hofstra University. Others who contributed materially to field work include Dr. Stuart A. Marks, Department of Behavioral Sciences, St. Andrews College, and Biol. Arturo Jiménez-G., Universidad de Nuevo León, México. Dr. Hugh H. Genoways, Texas Tech University, kindly reviewed the manuscript and provided editorial assistance.

#### LITERATURE CITED

- BIRNEY, E. C., AND R. TIMM. 1975. Dental ontogeny and adaptation in *Diphylla ecaudata*. *J. Mamm.*, 56:204-206.
- DISANTO, P. E. 1960. Anatomy and histochemistry of the salivary glands of the vampire bat, *Desmodus rotundus murinus*. *J. Morph.*, 106:301-335.
- EVERY, R. G., AND W. G. KÜHNE. 1971. Bimodal wear of mammalian teeth. Pp. 23-27, *in* Early mammals (D. M. Kermack and K. A. Kermack, eds.), Academic Press Inc., New York, v + 203 pp.
- FORMAN, G. L. 1972. Comparative morphological and histochemical studies of stomachs of selected American bats. *Univ. Kansas Sci. Bull.*, 49:591-729.
- FORMAN, G. L., R. J. BAKER, AND J. D. GERBER. 1968. Comments on the systematic status of vampire bats (family Desmodontidae). *Syst. Zool.*, 17:417-425.

- FULLMER, H. M. 1967. Connective tissue components of the periodontium. Pp. 349-414, in *Structural and chemical organization of teeth* (A. E. W. Miles, ed.), Academic Press, New York, 2:xv + 1-489.
- GLICKMAN, I. 1972. *Clinical periodontology*. W. B. Saunders Co., Philadelphia, vii + 1017 pp.
- GREENHALL, A. M. 1965. Notes on behavior of captive vampire bats. *Mammalia*, 25:441-445.
- . 1972. The biting and feeding habits of the vampire bats, *Desmodus rotundus*. *J. Zool.*, London, 168:451-461.
- HORST, R. 1968. Observations on the structure and function of the kidney of the vampire bat, *Desmodus rotundus murinus*. Ph.D. Dissertation, Cornell Univ., Ithaca, 123 pp.
- KALLEN, F. C., AND C. GANS. 1972. Mastication in the little brown bat, *Myotis lucifugus*. *J. Morph.*, 136:385-420.
- KLEVEZAL, G. A., AND S. E. KLEINENBERG. 1969. Age determination of mammals from annual layers in teeth and bones. *Acad. Sci., USSR* (translated into English), iii + 128 pp.
- KLINKHAMER, J. M. 1968. Saliva. Pp. 122-142, in *Dental biochemistry* (E. P. Lazzari, ed.), Lea and Febiger, Philadelphia, ix + 222 pp.
- LILLIE, R. D. 1965. *Histopathologic technic and practical histochemistry*. McGraw-Hill Book Co., New York, xii + 715 pp.
- MACINTYRE, G. T. 1966. The Miacidae, Part 1. *Bull. Amer. Mus. Nat. Hist.*, 131:117-209.
- MILLER, G. S., JR. 1896. Note on the milk dentition of *Desmodus*. *Proc. Biol. Soc. Washington*, 10:113-114.
- OSBORN, J. W. 1973. The evolution of dentitions. *Amer. Sci.*, 61:548-559.
- PHILLIPS, C. J. 1971. The dentition of glossophagine bats: development, morphological characteristics, variation, pathology, and evolution. *Misc. Publ. Mus. Nat. Hist., Univ. Kansas*, 54:1-138.
- PHILLIPS, C. J., AND B. OXBERRY. 1972. Comparative histology of molar dentitions of *Microtus* and *Clethrionomys*, with comments on dental evolution in microtine rodents. *J. Mamm.*, 53:1-20.
- PHILLIPS, C. J., G. W. GRIMES, AND G. L. FORMAN. n.d. Oral biology. In *Biology of bats of the New World family Phyllostomatidae. Part II* (R. J. Baker, J. K. Jones, Jr., and D. C. Carter, eds.), *Spec. Publ. Mus., Texas Tech Univ.*, in press.
- PINDBORG, J. J. 1970. Pathology of the dental hard tissues. W. B. Saunders Co., Philadelphia, 443 pp.
- SHACKLEFORD, J. M., AND W. H. WILBORN. 1968. Structural and histochemical diversity in mammalian salivary glands. *Alabama J. Med. Sci.*, 5:180-203.
- SLAUGHTER, B. H. 1970. Evolutionary trends in chiropteran dentitions. Pp. 51-83, in *About bats* (B. H. Slaughter and D. W. Walton, eds.), Southern Methodist Univ. Press, Dallas, xii + 1-339.
- SICHER, H., AND S. N. BHASKAR. 1972. *Orban's oral histology and embryology*. The C. V. Mosby Co., St. Louis, xii + 393 pp.
- VILLA-R., B. 1966. Los murciélagos de México: su importancia en la economía y la salubridad—su clasificación sistemática. *Univ. Nac. Aut. México, Inst. Biol., México*, xvi + 491 pp.

S-NA-Lubbock

OCCASIONAL PAPERS  
THE MUSEUM  
TEXAS TECH UNIVERSITY

MUSEUM OF COMPARATIVE ZOOLOGY  
LIBRARY

SEP 13 1976

HARVARD  
UNIVERSITY

---

NUMBER 43

10 SEPTEMBER 1976

---

NEW CAVERNICOLOUS RHAGIDIIDAE FROM IDAHO,  
WASHINGTON, AND UTAH (PROSTIGMATA:  
ACARI: ARACHNIDA)

WILLIAM R. ELLIOTT

The cavernicole fauna of western North America has not received much attention until recent years. Lava caves, surprisingly, have yielded a wealth of cave-adapted species, which have been reported by Causey (1972), Peck (1973), Holsinger (1974), and Briggs (1974). Rhagidiid mites have been reported previously from eastern North American limestone caves, but a number of species still await description (Holsinger, 1965*a*, 1965*b*; Elliott and Strandtmann, 1971). No rhagidiids have been reported yet from western North America, except for Alaska and western Canada (Strandtmann, 1971). This report concerns a remarkable new genus discovered in lava caves of Idaho by Stewart B. Peck, and in Washington by Francis G. Howarth. A new species of *Rhagidia*, collected by Richard E. Graham, is reported also from a limestone cave in Utah. All measurements are in microns.

**Flabellorhagidia**, new genus

*Diagnosis*.—The following is based on the adults of both sexes. Medium to large (650-1100), soft-bodied mites with long legs; leg I, 1.4 to 2.3 times body length; all femora divided; apparently eyeless; chelicerae large, with three or four-cusped fixed digit; setae, especially those on the legs, long and finely ciliated; suture between propodasoma and metapodasoma faint; tibia II bears a large, unusual dorsoapical structure, here termed the flabellum, probably a large, highly modified rhagidial organ (r.o.); stellate seta large, placed between first and second r.o. of tarsus I; stellate seta with large,

